

# A note on the possibility of identifying Leydig and Sertoli cells by immunohistochemistry in bowhead whales (*Balaena mysticetus*)

DEBRA L. MILLER\*, GREGORY D. BOSSART<sup>+</sup>, MEHRDAD NADJI<sup>#</sup>, RAYMOND TARPLEY\*\*, BRENDA ROBERTS<sup>++</sup> AND TODD M. O'HARA<sup>†</sup>

Contact e-mail: Todd.O'Hara@north-slope.org

## ABSTRACT

Leydig cells have been found to be either unidentifiable or at apparent low numbers during routine histologic examination of bowhead whale testes. Therefore, formalin-fixed, paraffin-embedded testicular tissues from 14 bowhead whales were retrospectively examined to determine if immunohistochemical staining could aid in identification of Sertoli and Leydig cells. Multiple intratesticular samples were examined when available. Sertoli and Leydig cells were differentiated using inhibin and calretinin stains. Significant whale length and seasonal differences were not found; however, a trend toward increased staining intensity was noted for autumn harvested whales.

KEYWORDS: BOWHEAD WHALE; HISTOLOGY; IMMUNOHISTOCHEMISTRY; REPRODUCTION

## INTRODUCTION

Obtaining a better understanding of the reproductive process is of particular importance in endangered species management. Such studies are especially challenging in migratory species because indices of reproduction may be affected by the intense physical demands of migration. Additionally, migration patterns often coincide with the breeding season, as is the case for bowhead whales (*Balaena mysticetus*) in Alaska (Koski *et al.*, 1993). The traditional timing of bowhead whale subsistence hunts in Barrow, during the spring and autumn, affords an opportunity for sampling and evaluating reproductive parameters at two periods in the annual migratory cycle (O'Hara *et al.*, 1999).

Biologists are interested in physical indicators of reproductive success. In testes, Sertoli cells are sustentacular or nurse cells for the developing gametes that are positioned basally within mammalian seminiferous tubules (Banks, 1986). They provide the physical support upon (or within) which the spermatogonia are embedded (Banks, 1986). They also secrete oestrogen and are metabolic regulators for developing gametes (Faulkner, 1969). Thus, they participate actively in the movement, development and release of the gametes. This participation makes them potentially valuable reproductive indicators. Similarly, Leydig cells are also a reproductive indicator because of their role in secreting testosterone, the male sex hormone. Leydig cells are the interstitial cells of the testes and are located within the septal connective tissue (Banks, 1986). Testosterone is the key stimulus for development of secondary sex characteristics and reproductive prowess (Faulkner, 1969).

Morphologic parameters (gross and microscopic) of testes have been used in many species to aid in assessment of reproductive status (e.g. Kobayashi *et al.*, 1996; Chapin, 1997; Hopkins and Spitzer, 1997; Short, 1997; O'Hara *et al.*, 2002). For example, in immature animals and during the non-breeding season in seasonal breeders, the epithelium of the seminiferous tubules is quiescent, with only scattered spermatogonia and Sertoli cells present (Banks, 1986). Examination of testicular morphology in bowheads has shown Leydig cells to be either unidentifiable or in low numbers in animals expected to be mature and active (O'Hara *et al.*, 2002). This inability to identify Leydig cells in bowhead whales compromises the assessment of sexual activity and seasonality, which are currently not well described. In humans, differences in the quantity and quality of Sertoli and Leydig cells have been demonstrated by immunohistochemistry (Forti *et al.*, 1992).

Although oestrogen and testosterone markers have been used to identify Sertoli and Leydig cells, respectively, additional markers have been identified and provide a means of identifying non-functional or inactive cells. For Sertoli cells, testis-specific proteins (i.e. inhibin and androgen binding protein) may serve to identify their presence (Forti *et al.*, 1989; Bergh and Cajander, 1990; Vleigen *et al.*, 1993). Specifically, inhibin is a peptide hormone that is a product of primarily Sertoli cells and minimally Leydig cells (Bergh and Cajander, 1990). Likewise, calretinin, a calcium-binding protein important in neurogenesis and neuroprotective mechanisms is thought to correlate with androgen status in males and has been valuable in identifying Leydig cells (Lephart *et al.*, 1998; Lephart and Watson, 1999). The purpose of this study is to identify a technique to specifically distinguish and describe the Leydig and Sertoli cells in

\* Department of Pathology, The University of Georgia College of Veterinary Medicine, Veterinary Diagnostic and Investigational Laboratory, Tifton, Georgia, 31793, USA.

<sup>+</sup> Harbor Branch Oceanographic Institute, 5600 US 1 North, Fort Pierce, Florida, 34946, USA.

<sup>#</sup> Department of Pathology, University of Miami School of Medicine, Miami, Florida, 33136, USA.

\*\* Texas A & M University, College of Veterinary Medicine, College Station, TX, 77843, USA.

<sup>++</sup> Department of Pathology, University of Miami School of Medicine, Miami, Florida, 33136, USA.

<sup>†</sup> North Slope Borough Department of Wildlife Management, Barrow, Alaska, 99723, USA.

bowhead whale testes. This information will be used to consider seasonality and interpret testosterone data and unusual cases, such as pseudohermaphrodites, in animals harvested in the autumn and spring.

## MATERIALS AND METHODS

### Sample collection

Testes were opportunistically collected from bowhead whales by the Department of Wildlife Management, North Slope Borough, Alaska. Historically, testicular samples have been collected from three locations, outer (near the tunic), middle and central (O'Hara *et al.*, 2002). All specimens were formalin-fixed, paraffin embedded and prepared on glass slides for staining and histologic examination. Standard haematoxylin and eosin staining protocol was used for initial light microscopic examination.

### Immunohistochemistry

Immunohistochemical staining success can be limited by antibody specificity for the targeted antigen. Therefore, species variation can result in false negatives. Lack of specific antibodies for whale tissue antigens necessitates that a chosen target (protein, cell type, product), and associated antibody, is fairly well conserved among mammalian species. This study included testosterone (rabbit anti-testosterone<sup>1</sup>), oestrogen receptor, progesterone receptor and androgen binding protein (mouse anti-human<sup>2</sup>) antibodies for staining testicular tissue. All four of these resulted in negative staining, most likely due to species variation of the antibodies for these products. Antibodies to inhibin (mouse anti-human<sup>3</sup>) and calretinin (rabbit anti-calretinin<sup>4</sup>) yielded positive results for both Sertoli and Leydig cells; however, preferential staining was noted for Sertoli cells by inhibin and Leydig cells by calretinin. Therefore, inhibin and calretinin were used in this study to identify Sertoli and Leydig cells, respectively.

Immunohistochemical staining was performed by the University of Miami Pathology Reference Service Immunoperoxidase Laboratory, Miami, Florida (USA). A labelled streptavidin biotin procedure was used (Nadji and Morales, 1983). Biotin (Vitamin B6) has high affinity binding to avidin (egg white protein), which allows these molecules to be used for 'tagging' different proteins and other molecules. The reaction between biotin and avidin can serve as a low-energy, high-efficiency method of binding substances that are otherwise difficult to bind. In brief, tissue sections approximately 3µm thick were cut from paraffin blocks and placed on glass slides. These slide preparations were deparaffinised, rehydrated and treated with H<sub>2</sub>O<sub>2</sub>-methanol to block interference from endogenous enzymes. The specific primary antibody was added to the preparation and conjugated with biotin. Next, the detection molecule (peroxidase) conjugated to avidin (streptavidin peroxidase) was added and this preparation was incubated at room temperature for 30 minutes. Specific binding of biotin to avidin allows for localisation of the detection molecule over a target antigen, which can then be visualised by addition of a chromagenic substance for the detection molecule (enzyme). Slide preparations were viewed under

light microscopy. Staining intensity was graded on a scale of 0-4, with 0 being no staining and 4 being the highest intensity of staining observed.

### Morphological measurements

Seminiferous tubules were measured with light microscopy as described in O'Hara *et al.* (2002) from haematoxylin and eosin stained slide preparations. Leydig cells were measured with light microscopy from immunohistochemically stained slide preparations following Clarke *et al.* (1994). In summary, two cells were measured from each of five fields for a total of 10 cells per sample. The widths and the lengths of the Leydig cells (given that they are round to oval structures) were measured using a micrometer and the averages (of the widths and the lengths) were calculated.

### Statistics

Means, standard deviation and Student's *t*-test were derived using *Microsoft Excel 2000*. Means and standard deviations were calculated for each dataset (calretinin staining, inhibin staining, seminiferous tubule diameter and Leydig cell dimensions) and within each dataset by season. A Student's *t*-test was used to compare datasets by whale length and by season.

## RESULTS

Positive intracytoplasmic staining was present for inhibin and calretinin (Figs 1 and 2). Inhibin staining was generally more intense than the calretinin staining (Figs 1 and 2); although in two pseudohermaphrodites, the staining intensity was reversed. No significant differences ( $p > 0.05$ ) were found in the size of Leydig cells or staining intensity of calretinin or inhibin in relation to whale length (Table 1). The specimens examined were from various intratesticular locations. In one whale, multiple locations were examined but no differences in staining intensity were noted. Significant ( $p < 0.05$ ) differences were noted in seminiferous tubule diameter in comparisons between whales greater and less than 12m, but not in comparisons between whales greater and less than 9m. Different Leydig cell diameters were noted between whales greater and less than 9m if  $p < 0.10$  is considered significant, but not between whales greater and less than 12m ( $p = 0.16$ ). Spermatozoa were not observed within the sections used for these immunohistochemical stains.

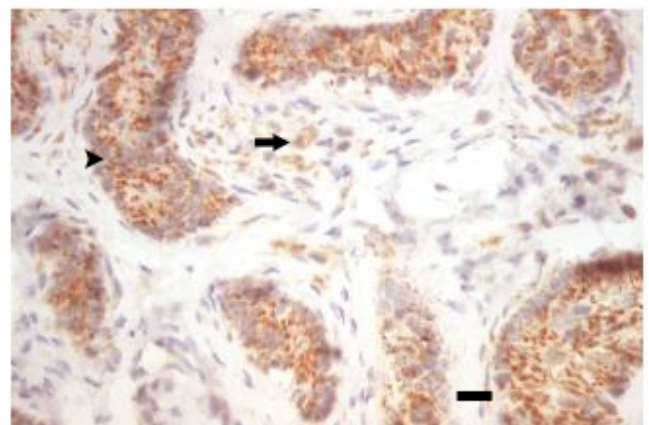


Fig. 1. Positive immunohistochemical staining for inhibin with identification of Sertoli cells (arrowhead) and Leydig cells (arrow) in the testis of a bowhead whale (*Balaena mysticetus*). Bar = 15µ.

<sup>1</sup> BioGenex, 4600 Norris Canyon Road, San Ramon, California, USA.

<sup>2</sup> DAKO Corporation, 6392 Via Real, Carpinteria, California, USA.

<sup>3</sup> Serotec Incorporated, 3200 Atlantic Avenue, Suite 105, Raleigh, North Carolina, USA.

<sup>4</sup> Zymed Laboratories, Inc., 561 Eccles Avenue, South San Francisco, California, USA.

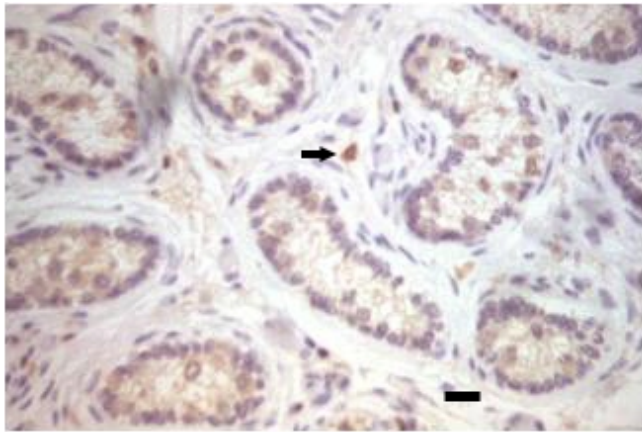


Fig. 2. Positive immunohistochemical staining for calretinin with identification of Leydig cells (arrow) in the testis of a bowhead whale (*Balaena mysticetus*). Bar = 20µ.

**DISCUSSION**

In general, staining intensity was greater for inhibin than for calretinin; however, Leydig cells were more easily viewed in calretinin stained sections. The variation in intensity might be ascribed to species compatibility to the antibodies and/or quantity of product present in the tissue; however, two pseudohermaphrodites that were included in the study displayed the opposite results for staining intensity (i.e. the calretinin stained much more intensely than the inhibin). Therefore, the quantity of antigen that is present in the tissue is a more likely explanation for this variation in stain intensity than species compatibility.

Sertoli cells are the primary producers of inhibin in males. Leydig cells have been shown to produce minimal amounts of inhibin in humans (Bergh and Cajander, 1990). There remains some debate as to whether or not other testicular sources of inhibin exist but attempts to identify other sources have been inconclusive, especially in adult mammals (Bergh and Cajander, 1990; Meachem *et al.*, 2001). Germ cells have

been shown to affect the amount of inhibin production in other mammals but the effects have varied (Bergh and Cajander, 1990; Meachem *et al.*, 2001; Clifton *et al.*, 2002). Additionally, Bergh and Cajander (1990) suggest that inhibin production may reflect both Sertoli and Leydig cell function. The intratubular positive staining for inhibin in the bowhead whale is presumed to reflect the framework provided by the cytoplasm of the Sertoli cells. Other intratubular sources of positive staining were not identified but cannot be ruled out. It is uncertain if the quantity of positive staining for inhibin in the bowhead whale is reflective of either Sertoli or Leydig cell function, but combining these data with serum hormone analysis (i.e. for FSH, inhibin, oestrogen and testosterone) may aid in understanding of the reproductive physiology in this species.

Minimal variation in calretinin and inhibin staining of testicular tissue was noted by length and season. This lack of significant variation in staining intensity by whale length was surprising. Sexual maturity is thought to take place at approximately 25 years of age, which for males corresponds to a length of 12-13m (George *et al.*, 1999) or 12.5-13m (O’Hara *et al.*, 2002). Therefore, males less than 9m are considered immature or young adults. Further investigation, including serum hormone analysis, is required to interpret the positive staining in the immature animals.

Staining intensity seemed to vary between animals that were of similar size but harvested in different seasons (83WW2 versus 82KK1; 96V148 versus 85B2; and 80B5 versus 81H4 versus 98B19). More intense staining was noted among autumn-harvested animals that might indicate seasonal fluctuation in function or differences in sampling or preservation (Table 1). This may suggest a seasonally dependent proliferation or ‘turning on’ of the cells in response to increased hormonal production, and additional samples are being collected to clarify this. Increased hormonal production in the autumn would coincide with the time preceding migration to the presumed breeding grounds. Koski *et al.* (1993) state that the principal mating period of

Table 1  
Immunohistochemical staining intensities (0-4) for calretinin (calret) and inhibin in bowhead whale (*Balaena mysticetus*) testes.

Whale ID	Whale length (m)	Year	Season	Calret	Inhibin	Seminiferous tubule diameter (µm)	Leydig cell dimensions (µm <sup>2</sup> )
81WW3 <sup>a</sup>	17.70	1983	S	2	1	50.8	6.2 × 9.2
83WW2	16.20	1983	S	2	2	102.8	9.2 × 10.8
82KK1	16.00	1982	F	2	3	62.0	7.7 × 7.7
83WW1 <sup>a</sup>	15.90	1983	S	3	2	58.4	9.2 × 13.9
84WW2	14.80	1984	S	0	0	75.9	-
96V150	13.60	1996	F	0	0	69.0	-
96V148	12.60	1996	F	4	4	45.8	8.5 × 10.8
85B2	12.20	1985	S	3	4	39.0	9.2 × 13.9
80B5	10.40	1980	S	1	2	44.9	11.6 × 13.9
81H4	10.00	1981	S	1	1	45.4	7.7 × 7.7
98B19	9.52	1998	F	3	4	50.55	8.5 × 8.5
82G1	7.92	1982	S	2	4	37.5	7.7 × 9.2
80WW1	7.80	1980	S	1	2	39.8	7.7 × 7.7
84WW1	7.60	1984	S	2	4	42.3	7.7 × 7.7
Total average	12.30			1.86	2.36	54.58	8.41 × 10.08
Spring average (n=10)	12.05			1.70	2.20	53.68	8.47 × 10.44
Fall average (n=10)	12.93			2.25	2.75	56.85	8.23 × 9.00
Total SD	3.48			1.17	1.50	18.07	1.33   2.55
Spring SD	3.85			0.95	1.40	20.77	1.54   2.77
Fall SD	2.68			1.71	2.05	10.57	0.46   1.61
Students <i>t</i> -test <sup>b</sup> by whale length (<12 vs >12)				0.83	0.49	0.04	0.16
Students <i>t</i> -test <sup>b</sup> by whale length (<9 vs >9)				0.90	0.31	0.14	0.08
Students <i>t</i> -test <sup>d</sup> by season				0.45	0.56		

<sup>a</sup>Pseudohermaphrodite (PH). <sup>b</sup>Analysis excludes PH.

the bowhead whale remains unknown; however, based on data from foetuses found in females at harvesting, most conceptions may occur during the late winter or spring. Similarly, Mogoe *et al.* (2000) reported a functional reduction of the southern minke whale (*Balaenoptera acutorostrata*) testis during the feeding season; and also found a corresponding decline in plasma testosterone concentration. Contemporaneous plasma testosterone concentrations are needed to further characterise the observations in this bowhead whale study.

A significant difference in seminiferous tubule diameter was observed between whales greater than and less than 12m (approximately the length at sexual maturity). Similar and expected findings were not noted in comparisons of Leydig cell diameters by whale length; possible differences in Leydig cell diameters were noted when comparing whales greater versus less than 9m ( $p = 0.08$ ). Based on their body lengths, these whales were most likely pubertal males and therefore, their testes were undergoing development. Clarke *et al.* (1994) found that Leydig cell size varies with maturity and that pubertal whales have Leydig cells that range from immature to mature depending upon the location within the testes. Adequate intratesticular comparisons regarding Leydig cell diameter cannot be made based on the sections examined in this study.

Negative staining results for animals 84WW2 and 96V150 were most likely due to sample handling. Factors such as tissue autolysis or prolonged formalin storage prior to paraffin embedding can affect immunohistochemical staining (Nadji and Morales, 1983). Times associated with sample handling were not known for these tissues.

The positive staining of the pseudohermaphrodite testicular tissues is interesting and: (1) may indicate testicular function in these animals; or (2) may imply that positive staining in normal tissues cannot be correlated with degree of function or activity. Tarpley *et al.* (1995) noted that the external phenotype in these whales was female but they described the gonads as underdeveloped testes. They noted that the cellular composition of the seminiferous tubules were limited to Sertoli cells and spermatogonia whereas the interstitium was primarily dense collagen, similar to that described for normal males. Active spermatogenesis was not found in the pseudohermaphrodites and anatomically the epididymis, ductus deferens and prostate gland were not present; however, neither were uterine structures. The karyotypes of these whales were XY and chromosomes were morphologically normal with a diploid number of 42. Given these morphological findings, the positive staining for Sertoli cells is not surprising; however, the positive staining for Leydig cells suggests that they may have been present but were not distinguishable with conventional stains (i.e. hematoxylin and eosin) as was the case for the normal males. These data show that such pseudohermaphroditic whales are reproductively deficient based on the anatomical and physiologic studies.

Future work should include correlation of these immunohistochemical findings with oestrogen and testosterone levels from archived serum samples. Correlating these findings with associated serum testosterone and oestrogen levels may aid in interpretation of the reproductive cycle (seasonality) of bowhead whales. Further, unusual cases, such as the pseudohermaphrodites, may be more thoroughly interpreted. These data will improve understanding of the reproductive physiology of this species, particularly the possibility that male bowhead whales vary seasonally in functional maturity and sperm production.

## ACKNOWLEDGEMENTS

We thank T. Albert for his support of this project, and for his and V. Woshner's editorial comments in preparation of this manuscript. We also thank the subsistence whale hunters for allowing us to collect the samples used in this study. Many assisted with sample collection and we are grateful for their help, particularly, L.M. Philo, P. Nader, D. Ramey and V. Woshner. Much appreciation goes to M. Dossey for the long hours spent sifting through archived specimens and for packaging and shipping them at a moments notice. Finally, we appreciate the comments of two anonymous reviewers.

## REFERENCES

- Banks, W.J. 1986. *Applied Veterinary Histology*. 2nd Edn. Williams and Wilkins, Baltimore, MD. 583pp.
- Bergh, A. and Cajander, S. 1990. Immunohistochemical localization of inhibin- $\alpha$  in the testes of normal men and in men with testicular disorders. *Int. J. Androl.* 13:463-9.
- Chapin, R.E. 1997. The relationships among reproductive endpoints in Swiss mice, using the reproductive assessment by continuous breeding database. *Fundam. Appl. Toxicol.* 38(2):129-42.
- Clarke, R., Paliza, O. and Aguayo, A.L. 1994. Sperm whales of the southeast Pacific. Part VI. Growth and breeding in the male. *Invest. Cetacea XXV*:93-224.
- Clifton, R.J., O'Donnell, L. and Robertson, D.M. 2002. Pachytene spermatocytes in co-culture inhibit rat Sertoli cell synthesis of inhibin betaB-subunit and inhibin B but not the inhibin alpha-subunit. *J. Endocrinol.* 172(3):565-74.
- Faulkner, L.C. 1969. Male reproduction. pp. 155-295. In: L.E. McDonald (ed.) *Veterinary Endocrinology and Reproduction*. Lea and Febiger, Philadelphia. 460pp.
- Forti, G., Barni, T., Vanelli, B.G., Balboni, G.C., Orlando, C. and Serio, M. 1989. Sertoli cell proteins in the human seminiferous tubule. *Journal of Steroid Biochemistry* 32(18):135-44.
- Forti, G., Vannelli, G.B., Barni, T., Balboni, G.C., Orlando, C. and Serio, M. 1992. Sertoli-germ cells interactions in the human testis. *J. Steroid. Biochem. Mol. Biol.* 43(5):419-22.
- George, J.C., Bada, J., Zeh, J., Scott, L., Brown, S.E., O'Hara, T. and Suydam, R. 1999. Age and growth estimates of bowhead whales (*Balaena mysticetus*) via aspartic racemization. *Can. J. Zool.* 77:571-80.
- Hopkins, F.M. and Spitzer, J.C. 1997. The new Society for Theriogenology breeding soundness evaluation system. *Vet. Clin. N. Am. Food Anim. Pract.* 13(2):283-93.
- Kobayashi, H., Urashima, M., Hoshi, Y., Uchiyama, H., Fujisawa, K., Akatsuka, J., Maekawa, K. and Hurusato, M. 1996. Testicular morphological changes in children with acute lymphoblastic leukemia following chemotherapy. *Acta Paediatr. Jpn* 38(6):640-3.
- Koski, W.R., Davis, R.A., Miller, G.W. and Withrow, D.E. 1993. Reproduction. pp. 239-74. In: J.J. Burns, J.J. Montague and C.J. Cowles (eds.) *The Bowhead Whale*. 1st. Edn. Society for Marine Mammalogy, Lawrence, Kansas. Special Publication. No.2. 787pp.
- Lephart, E.D. and Watson, M.A. 1999. Maternal separation: hypothalamic-preoptic area and hippocampal calbindin-D28K and calretinin in male and female infant rats. *Neurosci. Lett.* 267(1):41-4.
- Lephart, E.D., Taylor, H., Jacobson, N.A. and Watson, M.A. 1998. Calretinin and calbindin-D28K in male rats during postnatal development. *Neurobiol. Aging* 19(3):253-7.
- Meachem, S.J., Neischlag, E. and Simoni, M. 2001. Inhibin B in male reproduction: pathophysiology and clinical relevance. *Eur. J. Endocrinol.* 145(5):561-71.
- Mogoe, T., Takatoshi, S., Asada, M. and Fukui, Y. 2000. Functional reduction of the southern minke whale (*Balaenoptera acutorostrata*) testis during the feeding season. *Mar. Mammal Sci.* 16(3):559-69.
- Nadji, M. and Morales, A.R. 1983. Immunoperoxidase: Part I. The technique and its pitfalls. *Lab. Med.* 14(12):767-71.
- O'Hara, T.M., Albert, T.F., Oen, E.O., Philo, L.M., George, J.C. and Ingling, A.L. 1999. The role of Eskimo hunters, veterinarians, and other biologists in improving the humane aspects of the subsistence harvest of bowhead whales. *J. Am. Vet. Med. Assoc.* 214(8):1193-8.
- O'Hara, T.M., George, J.C., Tarpley, R.J., Burek, K. and Suydam, R.S. 2002. Sexual maturation in male bowhead whales (*Balaena mysticetus*) of the Bering-Chukchi-Beaufort Seas stock. *J. Cetacean Res. Manage.* 4(2):143-48.

Short, R.V. 1997. The testis, the witness of the mating system; the site of mutation and the engine of desire. *Acta Paediatr. Suppl.* 422:3-7.

Tarpley, R.J., Jarrell, G.H., George, J.C., Cabbage, J. and Stott, G.G. 1995. Male pseudohermaphroditism in the bowhead whale, *Balaena mysticetus*. *J. Mammal.* 76(4):1267-75.

Vleigen, M.K., Schlatt, S., Weinbauer, G.F., Bergmann, M., Groome, N.P. and Nieschlag, E. 1993. Localization of inhibin/activin subunits in the testis of adult nonhuman primates and men. *Cell Tissue Res.* 273:261-8.